

## Anomalous extensor tendons of hand: a case report with clinical importance

SHIPRA PAUL, M.D.<sup>1</sup>, SRIJIT DAS, M.S.<sup>2</sup>

### SUMMARY

The extensor digitorum muscle of the hand originates from the common extensor origin i.e., from the lateral epicondyle of the humerus and ends in four tendons, one for each digit except for the thumb. This paper reports a case, in which the tendon of the extensor digitorum ended as four tendons to the index, middle, ring and little fingers, but displayed variations in the number of tendons to each finger. Two tendons of extensor digitorum were observed in the ring and the little finger. Such an arrangement of the tendons of the extensor digitorum may have clinical importance. The presence of multiple tendons may also alter the kinematics around the site of attachment to the phalanx. Knowledge of abnormal and normal anatomy of the extensor tendons, may be helpful while performing graft and tendon transfer operations.

*Keywords: Anatomy; Palm; Tendon; Anomalies; Variations.*

### *Tendones anómalos del extensor de la mano y su importancia clínica*

### RESUMEN

El músculo extensor de los dedos de la mano se origina a partir del comienzo del extensor común, es decir, del epicóndilo lateral del húmero y termina en cuatro tendones, uno para cada dedo, excepto el pulgar. Este trabajo informa un caso donde el tendón del extensor de los dedos terminaba como cuatro tendones para los dedos índice, medio, anular y meñique, pero mostraba variaciones en el número de tendones para cada dedo. En efecto, se observaron dos tendones en los dedos anular y meñique. Tal disposición de los tendones del extensor de los dedos puede tener importancia clínica. La presencia de tendones múltiples puede también alterar la cinética alrededor del sitio de inserción a la falange. El conocimiento de la anatomía normal y anormal de los tendones extensores es de utilidad cuando se hacen cirugías como transferencia de tendones e injertos.

*Palabras clave: Anatomía; Tendones; Anomalías; Variaciones.*

The extensor digitorum muscle (EDM) originates from the lateral condyle of the humerus via the common extensor tendon, the adjacent intermuscular septa and the antebrachial fascia<sup>1,2</sup>. It divides distally into four tendons which pass in a common synovial sheath with the tendon of extensor indicis, through a tunnel under the extensor retinaculum and diverge on the dorsum of the hand, one to each finger<sup>1,2</sup>. The tendon to the index finger is accompanied by the extensor indicis which lies medial (ulnar) to it. Three variable intertendinous connections (juncturae tendinae) are found on the dorsum of the hand, which are inclined distally and radially<sup>2</sup>.

The tendons of extensor digitorum may be variably

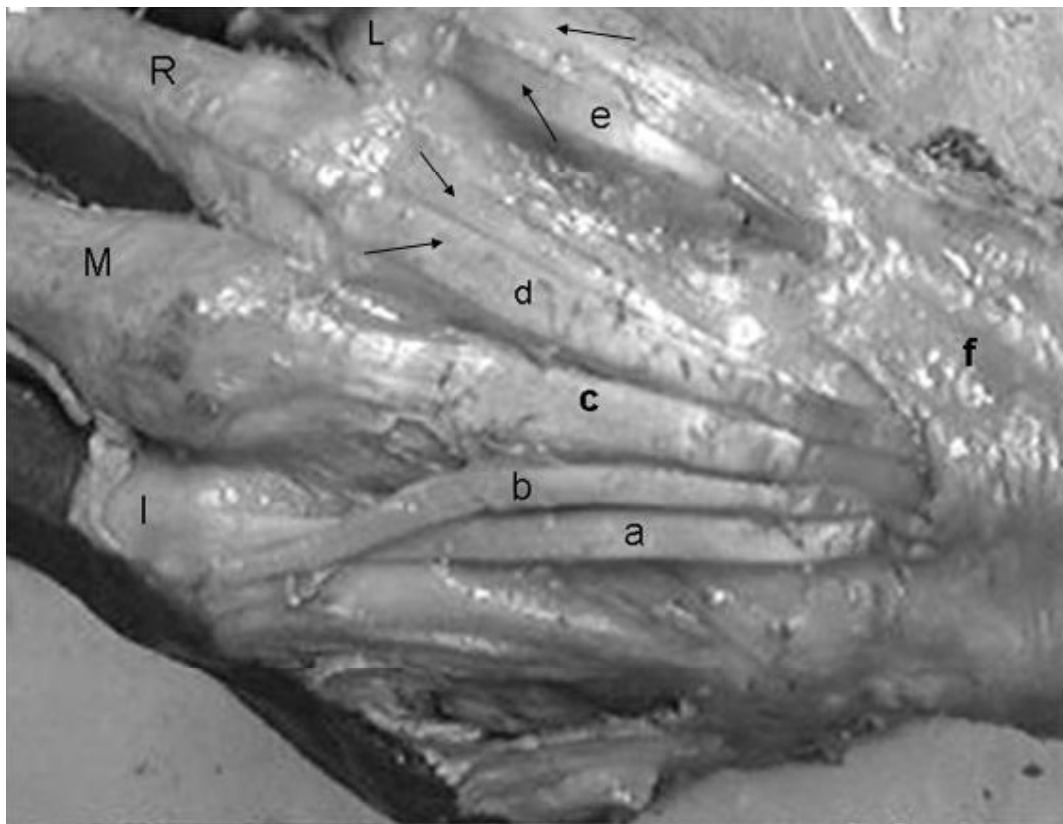
deficient. More common they are doubled or even tripled in one or more digits, most often the index finger or the middle finger<sup>1,2</sup>. A slip may pass occasionally to the thumb. The arrangement of the intertendinous connections on the dorsum of the hand, is variable. The medial connection is strong and pulls the tendon of the little finger towards that of the ring finger, whereas the connection between the middle two tendons is weak and may be absent.

Anatomical variations in the extensor tendons are common. Double or triple extensor digitorum communis (EDC) to long fingers, single or triple EDC to ring finger and single or double EDC to small finger<sup>3</sup>. Arising from the common extensor origin the muscle expands into a rounded

1. Director Professor, Department of Anatomy, Maulana Azad Medical College, Bahadur Shah Zafar Marg, New Delhi-110002, India. e-mail: drshipra14@yahoo.com

2. Associate Professor, Department of Anatomy, Maulana Azad Medical College, Bahadur Shah Zafar Marg, New Delhi-110002, India. e-mail: das\_srijit23@rediffmail.com

Recibido para publicación noviembre 23, 2006 Aceptado para publicación abril 16, 2007



**Photo 1. Photograph of dorsum of hand showing: a. Tendon of extensor indicis; b. Tendon of EDM to index finger; c. Thickened tendon of EDM to middle finger; d. Anomalous tendon to ring finger (double tendon shown with arrows); e. Anomalous tendons to little finger (double tendon shown with arrows); I. Index finger; M. Middle finger; R. Ring finger; L. Little finger; f. Extensor retinaculum.**

belly in the middle of the forearm, diverging from the three muscles on the radial side and separated from them by the emergence of the thumb extensors<sup>2</sup>. Its four tendons pass under the extensor retinaculum crowded together, overlying the tendon of extensor indicis. On the back of the hand, the tendons spread out towards the fingers. Commonly the fourth tendon is fused with that to the ring finger, and reaches the little finger only by a tendinous band that passes across near the metacarpo-phalangeal joint. Other bands join adjacent tendons in a variable manner<sup>2</sup>.

The anatomy of the variations of the EDM is important for successful treatment of De Quervain disease, where the tenosynovectomy has to be performed. The anatomical knowledge of the arrangement of the extensor tendons and its morphological variations may also be important for hand surgeons performing tendon transfers and grafts. The present study, reports the variations of the EDM and discusses its clinical importance.

## CASE REPORT

During routine dissection of cadavers for undergraduate medical students, we detected an anomalous extensor digitorum muscle, unilaterally on the right side of a 45 year old male cadaver. The anomalous extensor digitorum muscle was dissected carefully to expose its origin, course and insertion. The specimen was photographed (Photo 1).

## OBSERVATION

The extensor digitorum tendon originated from the lateral condyle of the humerus via the common extensor tendon and passed deep to extensor retinaculum to continue its course towards the digits. The tendon to the index finger was single and was accompanied by the extensor indicis tendon. The tendon to the middle finger was much thickened and the tendon to the ring and little finger were double in

number (marked with arrows in Photo 1). The insertion was usual to the distal aspect of the base of the distal phalanx. The EDM was innervated as usual by the posterior interosseous nerve. No other abnormalities were observed.

## DISCUSSION

In the present case, the origin and the insertion of the EDM were as usual but displayed variations in the number of tendons to the different digits. There was a single tendon to the index finger, whereas the tendon to the middle finger was much thicker, with the fourth and fifth finger receiving double slips. Considering the fact that the EDM causes extension of the interphalangeal and metacarpophalangeal joints, the presence of double tendons to the ring and the little finger may certainly influence the different direction of the pull, at these joints.

The EDM has been reported to display variations with regards to the number of tendons. A past study has reported one tendon to the index finger, one to the middle finger, two to the ring finger, and none to the little finger<sup>4</sup>. Research studies have described multiple tendons to the middle and the ring finger<sup>5</sup>. In the present case, there was double tendon to the ring and the little finger which may be considered a rare variation of its kind. These types of variations are only incidental findings and we do admit that regarding these anomalies, a series of observations over a sufficient number of years in multiple cadavers are sure to add more vigor to the existing knowledge.

The embryological explanation for such an anomaly can be explained by the fact that the precursor extensor muscle mass differentiates mainly into three bundles - the superficial extensor digitorum communis, extensor carpi ulnaris and the extensor digiti quinti proprius and the anomalies related to the extensor muscle are commonly due to an early developmental defect related to the developing extensor sheet of the forearm<sup>6</sup>.

Anatomical knowledge of the extensor tendons is important for successful tenosynovectomy in the treatment of De Quervain disease<sup>7</sup>. Knowledge of anomalous extensor tendons may also be helpful in identifying and planning tendon transfer or graft surgeries. Presence of multiple tendons may be beneficial in tendon transfer operations. A research study had advocated the selection of appropriate tendon slip for transfer to be aided by the recognition of the anatomical anomalies<sup>8</sup>. Synovitis of the extensor tendons occurs in 30% of cases of patients of rheumatoid arthritis and rupture of the tendons are more common in the extensor tendons of 4<sup>th</sup> and 5<sup>th</sup> digits and in extensor pollicis longus<sup>9</sup>. Thus, anomalies of extensor tendons of 4<sup>th</sup> and 5<sup>th</sup> digits assume much importance as it is clinically important for all tendon transplant surgeries.

## REFERENCES

1. Standring S. *Gray's anatomy. The anatomical basis of clinical practice*. New York: Elsevier Churchill Livingstone; 2005. p. 880.
2. Sinnatamby CS. *Last's anatomy. Regional and applied*. Edinburgh: Churchill Livingstone; 2001. p. 71.
3. von Schroeder HP, Botte MJ. Anatomy of the extensor tendons of the fingers: variations and multiplicity. *J Hand Surg [Am]* 1995; 20: 27-34.
4. Zilber S, Oberlin C. Anatomical variations of the extensor tendons to the fingers over the dorsum of the hand: a study of 50 hands and a review of the literature. *Plast Reconstr Surg* 2004; 113: 214-221.
5. el-Badawi MG, Butt MM, al-Zuhair AG, Fadel RA. Extensor tendons of the fingers: arrangement and variations-ii. *Clin Anat* 1995; 8: 391-398.
6. Abu-Hijleh MF. Extensor pollicis tertius: an additional extensor muscle to the thumb. *Plast Reconstr Surg* 1993; 92: 340-343.
7. Shiraishi N, Matsumura G. Anatomical variations of the extensor pollicis brevis tendon and abductor pollicis longus tendon-relation to tenosynovectomy. *Okajimas Folia Anat Jpn* 2005; 82: 25-29.
8. Neviasser RJ, Wilson JN, Gardner MM. Abductor pollicis longus transfer for replacement of first dorsal interosseous. *J Hand Surg [Am]* 1980; 5: 53-57.
9. Harris NH, Birch R. *Postgraduate textbook of clinical orthopaedics*. Oxford: Blackwell Science; 1995. p. 542.

