

REVIEW

## Damage control in the emergency department, a bridge to life

### Control de daños en la sala de emergencias: un puente hacia la vida

Laureano Quintero<sup>1,2</sup>  Juan José Meléndez-Lugo<sup>3</sup>  Helmer Emilio Palacios-Rodríguez<sup>1</sup>   
Natalia Padilla<sup>4</sup>  Luis Fernando Pino<sup>1,5</sup>  Alberto García<sup>1,6,7</sup>  Adolfo González-Hadad<sup>1,2,6</sup>   
 Mario Alain Herrera<sup>1,6</sup>  Alexander Salcedo<sup>1,5,6,7</sup>  José Julián Serna<sup>1,5,6,7</sup>  Fernando  
Rodríguez-Holguín<sup>7</sup>  Michael W. Parra<sup>8</sup>  Carlos A. Ordoñez<sup>1,6,7</sup> 

[ordonezcarlosa@gmail.com](mailto:ordonezcarlosa@gmail.com), [carlos.ordonez@fvl.org.co](mailto:carlos.ordonez@fvl.org.co)



OPEN ACCESS

**Citation:** .Quintero L, Meléndez-Lugo JJ, Palacios-Rodríguez HE, Padilla N, Pino LF, Gacía A, González-Hadad A, Herrera MA, Salcedo A, Serna JJ, Rodríguez-Holguín F, Parra MW, Ordoñez CA. **Damage control in the emergency department, a bridge to life.** Colomb Méd (Cali), 2021; 52(2):e4004801 <http://doi.org/10.25100/cm.v52i2.4801>

**Received :** 30 Mar 2021  
**Revised:** 30 Apr 2021  
**Accepted :** 27 May 2021  
**Published:** 30 May 2021

**Keywords:**

Control de daños, Resucitación en trauma, Reanimación hemostática, Imágenes diagnósticas, REBOA, Evaluación enfocada con ecografía para traumatismo, Hipotermia, Hemorragia, Servicio de emergencia, Hospital, Conmoción, Hipotensión arterial, Intubación, intratraqueal, Oclusión con globo, Respiración de presión positiva, Servicios médicos de emergencia.

**1** Universidad del Valle, Facultad de Salud, Escuela de Medicina, Department of Surgery, Division of Trauma and Acute Care Surgery, Cali, Colombia., **2** Centro Médico Imbanaco, Cali, Colombia., **3** Caja Costarricense del Seguro Social, Department of Surgery, San José, Costa Rica., **4** Fundación Valle del Lili, Centro de Investigaciones Clínicas (CIC), Cali, Colombia, **5.** Hospital Universitario del Valle, Division of Trauma and Acute Care Surgery, Department of Surgery. , Cali, Colombia., **6 6.** Universidad Icesi, Cali, Colombia., **7** Fundación Valle del Lili, Department of Surgery, Division of Trauma and Acute Care Surgery, Cali, Colombia., **8** Broward General Level I Trauma Center, Department of Trauma Critical Care, Fort Lauderdale, FL - USA,

## Abstract

Patients with hemodynamic instability have a sustained systolic blood pressure less or equal to 90 mmHg, a heart rate greater or equal to 120 beats per minute and an acute compromise of the ventilation/oxygenation ratio and/or an altered state of consciousness upon admission. These patients have higher mortality rates due to massive hemorrhage, airway injury and/or impaired ventilation. Damage control resuscitation is a systematic approach that aims to limit physiologic deterioration through strategies that address the physiologic debt of trauma. This article aims to describe the experience earned by the Trauma and Emergency Surgery Group (CTE) of Cali, Colombia in the management of the severely injured trauma patient in the emergency department following the basic principles of damage control surgery. Since bleeding is the main cause of death, the management of the severely injured trauma patient in the emergency department requires a multidisciplinary team that performs damage control maneuvers aimed at rapidly controlling bleeding, hemostatic resuscitation, and/or prompt transfer to the operating room, if required.

**Palabras clave:**

Control de daños, Resucitación en trauma, Reanimación hemostática, Imágenes diagnósticas, REBOA, Evaluación enfocada con ecografía para traumatismo, Hipotermia, Hemorragia, Servicio de emergencia, Hospital, Conmoción, Hipotensión arterial, Intubación, intratraqueal, Oclusión con globo, Respiración de presión positiva, Servicios médicos de emergencia.

**Copyright:** © 2021 Universidad del Valle

**Conflicts of interest:**

The authors declare that they have no conflict of interest.

**Acknowledgments:**

For the illustrations and the design of the cover to the Anatomical Draftsman Fabian R. Cabrera P. Professor of the Design, Department of the Faculty of Integrated Arts of the Universidad del Valle. We acknowledge to Linda M. Gallego and Yaset Caicedo for their comments on the drafting of the manuscript.

**Corresponding author:**

**Carlos A. Ordonez**, MD, FACS.  
Division of Trauma and Acute Care Surgery, Department of Surgery, Fundación Valle del Lili, Cali, Colombia; Division of Trauma and Acute Care Surgery, Department of Surgery, Universidad del Valle, Cali, Colombia; Universidad Icesi, Cali, Colombia.

**e-mail:** [ordonezcarlosa@gmail.com](mailto:ordonezcarlosa@gmail.com), [carlos.ordonez@fvl.org.co](mailto:carlos.ordonez@fvl.org.co)

## Resumen

Un paciente politraumatizado hemodinámicamente inestable es aquel que ingresa al servicio de urgencias con una presión arterial sistólica menor o igual de 90 mmHg, una frecuencia cardíaca mayor o igual a 120 latidos por minuto y un compromiso agudo de la relación ventilación/oxigenación y/o del estado de conciencia. Por esta razón, existe una alta mortalidad dentro de las primeras horas de un trauma severo ya sea por una hemorragia masiva, una lesión de la vía aérea y/o una alteración de la ventilación. Siendo el objetivo de este artículo describir el manejo en urgencias del paciente politraumatizado hemodinámicamente inestable de acuerdo con los principios de control de daños. El manejo del paciente politraumatizado es una estrategia dinámica de alto impacto que requiere de un equipo multidisciplinario de experiencia. El cual debe de evolucionar conjunto a las nuevas herramientas de diagnóstico y tratamiento endovascular que buscan ser un puente para lograr una menor repercusión hemodinámica en el paciente y una más rápida y efectiva estabilización con mayores tasas de sobrevida.

### Remark

#### 1) Why was this study conducted?

This article aims to describe the experience earned by the Trauma and Emergency Surgery Group (CTE) of Cali, Colombia in the management of the severely injured trauma patient in the emergency department following the basic principles of damage control surgery.

#### 2) What were the most relevant results of the study?

The ATLS guidelines describe the A-B-C-D-E sequence, which consists of a clear and simple approach for severely injured trauma patients. Novel A-A-B-C-D-E sequence, where the initial "A-A" refers to achieving arterial and/or venous vascular access and airway control. Vascular access in common femoral artery and common femoral vein should be strategy to establish a way for massive transfusion protocol, invasive monitoring, and potential REBOA use.

#### 3) What do these results contribute?

The management of the severely injured trauma patient in the emergency department requires a multidisciplinary team that performs damage control maneuvers aimed at rapidly controlling bleeding, hemostatic resuscitation, and/or prompt transfer to the operating room, if required.

## Introduction

Patients with hemodynamic instability have a sustained systolic blood pressure less or equal to 90 mmHg, a heart rate greater or equal to 120 beats per minute and an acute compromise of the ventilation/oxygenation ratio and/or an altered state of consciousness upon admission. These patients have higher mortality rates due to massive hemorrhage, airway injury and/or impaired ventilation<sup>1</sup>. Damage control resuscitation is a systematic approach that aims to limit physiologic deterioration through strategies that address the physiologic debt of trauma<sup>2</sup>. The initial maneuvers implemented in the emergency department are: a primary survey by an experienced trauma team, diagnostic adjuncts such as chest X-ray, pelvic X-ray and Focused Assessment with Sonography for Trauma - FAST), temporary hemorrhage control maneuvers (tourniquet or pelvic binder/sheet), peripheral and central vascular accesses, massive transfusion protocol activation and endovascular aortic occlusion with the Resuscitative Endovascular Balloon Occlusion of the Aorta (REBOA)<sup>3,4</sup>.

This article describes the experience earned by the Trauma and Emergency Surgery Group (CTE) of Cali, Colombia, in managing severely injured trauma patients in the emergency department following the basic principles of damage control surgery. Therefore, a consensus was made to synthesize the experience earned during the past 30 years in trauma critical care management from the Trauma and Emergency Surgery Group (CTE) of Cali, Colombia, including experts from the the Universidad del Valle, University Hospital del Valle “Evaristo García”, University Hospital Fundación Valle del Lili, Universidad Icesi and, the Asociación Colombiana de Cirugía, the Pan-American Trauma Society and the collaboration of international specialists of the United States of America and Latin America.

## Epidemiology

Lozano *et al.*<sup>5</sup>, in a systematic analysis about the Global Burden of Disease between 1990 and 2010 found that 5.1 million people died as victims of trauma with an increase over the decades from 8.8% in the early 1990s to 9.6% by 2010. These trauma deaths affect predominantly young people with a large impact on economically useful life expectancy<sup>5,6</sup>. According to the Global Burden of Diseases, Injuries, and Risk Factors Study in 2019 (GBD 2019) the deaths from traumatic injuries decreased by 1.11% from 2010 to 2019.

## Concepts

The damage control strategy began around 1993 by Rotondo *et al.*<sup>2</sup>, who established three stages for the approach to severely injured trauma patients. Stage I consists of the control of bleeding and/or contamination, abdominal packing and temporary cavity closure; stage II in resuscitation and physiologic restoration in the intensive care unit and Stage III in surgical re-exploration, treatment and definitive closure. Subsequently, Johnson and collaborators included the prehospital scene as stage zero being crucial for adequate patient care<sup>7</sup>. Another fundamental concept in trauma is the lethal triad which includes: hypothermia, coagulopathy and acidosis secondary to acute physiological deterioration<sup>8</sup>. This concept was also expanded by Ditzel *et al.*<sup>9</sup>, proposed the lethal diamond of death with hypocalcemia as another fundamental concept.

During the last decades, the development and implementation of new diagnostic tools such as FAST and the whole body computed tomography provided important information that allows quick and organized decision-making with a highly detailed evaluation<sup>10,11</sup>. On the other hand, bleeding control and hemostatic resuscitation with transfusion of red blood cells, plasma and platelets in a 1:1:1 ratio have shown better results in restoring intravascular volume and hemostatic balance<sup>12</sup>. These maneuvers with the permissive hypotension avoid hypothermia, clotting factors dilution and blood loss from uncontrolled sources while maintaining sufficient blood pressure to ensure coronary and cerebral perfusion<sup>13</sup>.

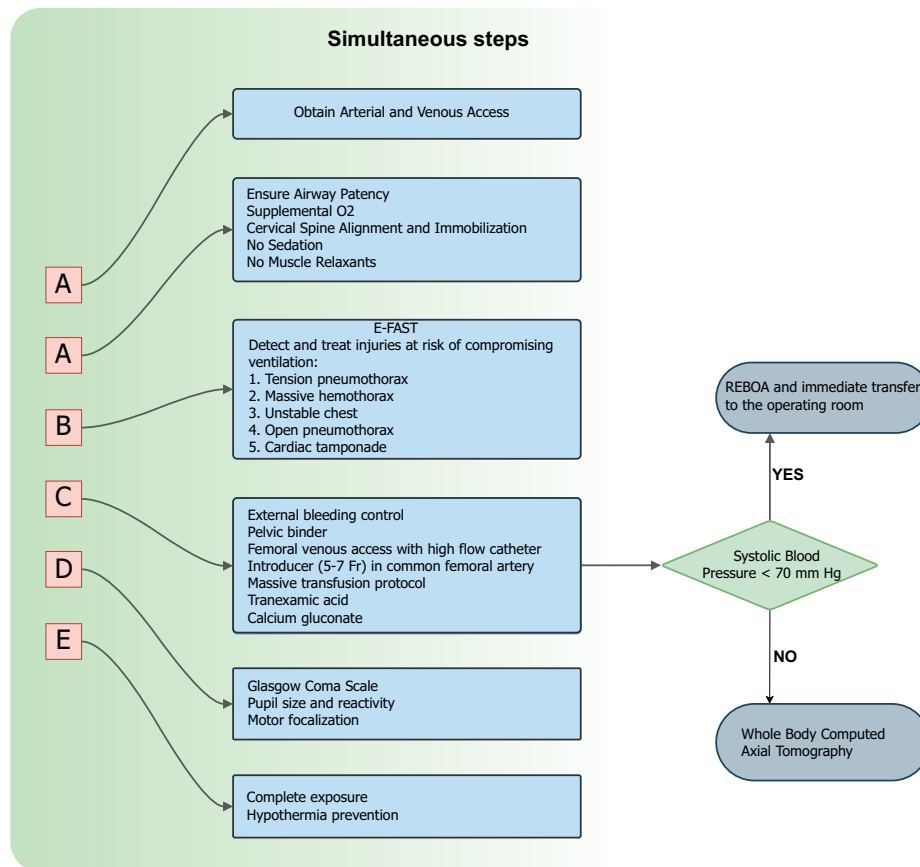


Figure 1. A-A-B-C-D-E management for a severe trauma patient

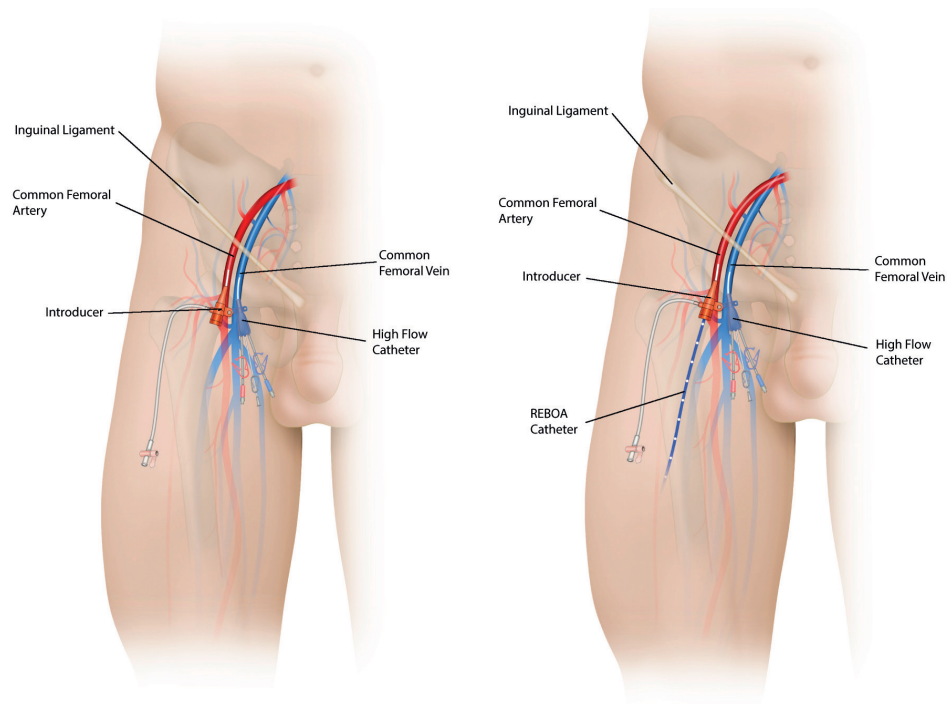
Also, REBOA has been consolidated as an additional endovascular tool that aids in the early control of hemorrhage and hemodynamic support<sup>14,15</sup>. In the United States of America, REBOA has been used for infra diaphragmatic injuries; however, our experience has shown promising clinical results even in thoracic trauma<sup>16,17</sup>. It is important to note that to carry out all the measures mentioned above. It is necessary to integrate a multidisciplinary trauma team, trained and organized and headed by a Trauma Surgeon who leads continuous and effective management.

### Damage control in the emergency department

The ATLS guidelines describe the A-B-C-D-E sequence, which consists of a clear and simple approach for severely injured trauma patients. This organized management allows a simultaneous evaluation by different members of the team with a certain degree of overlap between the phases. Recently, some authors proposed a modification to the ATLS sequence due to the advent of endovascular therapies; they suggest a new A-A-B-C-D-E sequence, where the initial “A-A” refers to achieving arterial and/or venous vascular access and airway control (Figure 1).

### ATLS assessment and resuscitation sequence: ABCDE

**A:** the airway should be protected and adequate ventilation should be secured. Supplemental oxygen must be administered to all severely injured trauma patients to achieve a 94-95% target saturation. Positive pressure ventilation, sedatives and muscle relaxants should be avoided due to its association with early circulatory collapse. In upper airway obstruction, an emergency cricothyroidotomy should be performed and in lower airway injuries, tracheal intubation guided by fiber bronchoscopy should be done. Also, the cervical spine must be protected from excessive mobility to prevent the development of or progression of a deficit.



**Figure 2.** Vascular access in the common femoral artery and common femoral vein for a patient with severe trauma should be established vascular accesses. Arterial access with introducer lower 7 Fr, if it is possible, should be placed and a high flow catheter in the common femoral vein to continue the hemostatic resuscitation maneuvers and invasive monitoring. If the patient is a non-responder, REBOA can be placed through arterial access in the common femoral artery.

**B:** Airway patency alone does not ensure adequate ventilation. Injuries that significantly impair ventilation in the short term include tension pneumothorax, massive hemothorax, unstable thorax, open pneumothorax and cardiac tamponade. The use of an extended FAST exam allows to identify and diagnosis all of these potential life-threatening injuries to treat them promptly and help to choose the optimal surgical management

**C:** During the primary survey, external hemorrhage should be identified and controlled by direct manual pressure on the wound or a tourniquet placement for an extremity. The internal source of hemorrhage should be managed with urgent surgical or endovascular interventions<sup>19,20</sup>. In the hemodynamically unstable patient, both a common femoral vein and artery lines should be placed for intravenous access and blood pressure monitoring<sup>21,22</sup> (Figure 2). Additionally, the institution's massive transfusion protocol should be activated, which includes four units of red blood cells, four units of plasma, 1 unit of apheresis platelets reserve, 1g of tranexamic acid and 20 ml of 10% calcium gluconate that should be administered according to the coagulation status of the patient<sup>23</sup>. If during the initial resuscitation the systolic blood pressure of the patient reaches 80-90 mm Hg, a whole-body computed tomography (WBCT) should be done. This technology has emerged as a highly sensitive and specific diagnostic tool that will aid in the decision-making of the best surgical approach without incurring any delay in definitive management and/or increasing the radiation exposure significantly. On the contrary, if the patient is not responder and systolic blood pressure continues equal or lower to 70 mm Hg, it is indicated to deploy a REBOA and immediately transferred to the emergency room.

**D:** A rapid neurologic evaluation should establish the patient's level of consciousness, pupillary size and reaction. Also, lateralizing and/or spinal cord injury signs should be identified.

**E:** full exposure and assessment of the anterior and posterior body space should be performed, followed by measures to prevent hypothermia.

Blood sampling for blood derivative crossmatching, arterial gas processing, fibrinogen, lactate and thromboelastogram will provide baseline values that predict and measure the severity of the trauma. However, resuscitation maneuvers should not be delayed while waiting for their results.

## Conclusions

The management of the severely injured trauma patient is a dynamic, high-impact strategy that requires an experienced multidisciplinary team, which must evolve with new diagnostic tools and endovascular treatment reducing the hemodynamic repercussions as a lifesaving approach with higher survival rates.

## References

1. Braz LG, Carlucci MTO, Braz JRC, Módolo NSP, do Nascimento P, Braz MG. Perioperative cardiac arrest and mortality in trauma patients: A systematic review of observational studies. *J Clin Anesth.* 2020; 64:109813. Doi: 10.1016/j.jclinane.2020.109813Braz LG, Carlucci MTO,
2. Rotondo MF, Schwab CW, McGonigal MD, Phillips 3rd GR, Fruchterman TM, Kauder DR, et al. "Damage control" an approach for improved survival in exsanguinating penetrating abdominal injury. *J Trauma Acute Care Surg.* 1993; 35(3): 375-82.
3. El Sayed MJ, Tamim H, Mailhac A, Mann NC. Trends and predictors of limb tourniquet use by civilian emergency medical services in the United States. *Prehospital Emerg Care.* 2017;21(1):54-62. doi: 10.1080/10903127.2016.1227002.
4. Costantini TW, Coimbra R, Holcomb JB, Podbielski JM, Catalano R, Blackburn A, et al. Current management of hemorrhage from severe pelvic fractures: Results of an American Association for the Surgery of Trauma multi-institutional trial. *J Trauma Acute Care Surg.* 2016;80(5):717-25. doi: 10.1097/TA.0000000000001034.
5. Lozano R, Naghavi M, Foreman K, Lim S, Shibuya K, Aboyans V, et al. Global and regional mortality from 235 causes of death for 20 age groups in 1990 and 2010: A systematic analysis for the Global Burden of Disease Study 2010. *Lancet.* 2012;380(9859):2095-128. doi: 10.1016/S0140-6736(12)61728-0.
6. Megevand B, Celi J, Niquille M. Choc hémorragique. *Rev Med Suisse.* 2014;10(438):1696-702.
7. Johnson JW, Gracias VH, Schwab CW, Reilly PM, Kauder DR, Shapiro MB, et al. Evolution in damage control for exsanguinating penetrating abdominal injury. *J Trauma.* 2001;51(2):261-71. doi: 10.1097/00005373-200108000-00007.
8. Bjerkvig CK, Strandenes G, Eliassen HS, Spinella PC, Fosse TK, Cap AP, et al. "Blood failure" time to view blood as an organ: How oxygen debt contributes to blood failure and its implications for remote damage control resuscitation. *Transfusion.* 2016; 56: S182-9. doi: 10.1111/trf.13500.
9. Ditzel RM, Anderson JL, Eisenhart WJ, Rankin CJ, DeFeo DR, Oak S, et al. A review of transfusion- And trauma-induced hypocalcemia: Is it time to change the lethal triad to the lethal diamond? *J Trauma Acute Care Surg.* 2020;88(3):434-9. doi: 10.1097/TA.0000000000002570.
10. Williams SR, Perera P, Gharahbaghian L. The FAST and E-FAST in 2013: Trauma Ultrasonography. Overview, practical techniques, controversies, and new frontiers. *Crit Care Clin.* 2014;30(1):119-50. Doi: 10.1016/j.ccc.2013.08.005
11. Ordoñez CA, García C, Parra MW, Angamarca E, Guzmán-Rodríguez M, Orlas CP, et al. Implementation of a new single-pass whole-body computed tomography protocol: Is it safe, effective and efficient in patients with severe trauma? *Colomb Med (Cali).* 2020;51(1): e4224. doi: 10.25100/cm.v51i1.4224.



12. Holcomb JB, Fox EE, Wade CE. The prospective observational multicenter major trauma transfusion (PROMMTT) study. *J Trauma Acute Care Surg.* 2013;75 (1 Suppl 1):S1-S2. DOI:10.1097/TA.0b013e3182983876.
13. Galvagno SM, Nahmias JT, Young DA. Advanced Trauma Life Support(r) Update 2019: Management and Applications for Adults and Special Populations. *Anesthesiol Clin.* 2019;37(1):13-32. doi: 10.1016/j.anc-lin.2018.09.009.
14. Rubin IL. Acute Cor Pulmonale. *Ann Intern Med.* 1950;33(4): 1013-6. doi: 10.7326/0003-4819-33-4-1013.
15. Morrison JJ, Percival TJ, Markov NP, Villamaria C, Scott DJ, Saches KA, et al. Aortic balloon occlusion is effective in controlling pelvic hemorrhage. *J Surg Res.* 2012;177(2):341-7. doi: 10.1016/j.jss.2012.04.035
16. Meléndez JJ, Ordóñez CA, Parra MW, Orlas CP, Manzano-Núñez R, García AF, et al. Balón de reanimación endovascular de aorta para pacientes en riesgo de o en choque hemorrágico: experiencia en un centro de trauma de Latinoamérica. *Rev Colomb Cirugía.* 2019;34(2):124-31. doi: 10.30944/20117582.106
17. Ordoñez CA, Parra MW, Manzano-Nunez R, Herrera-Escobar JP, Serna JJ, Rodríguez Ossa P, et al. Intraoperative combination of resuscitative endovascular balloon occlusion of the aorta and a median sternotomy in hemodynamically unstable patients with penetrating chest trauma: Is this feasible? *J Trauma Acute Care Surg.* 2018;84(5):752-7. doi: 10.1097/TA.0000000000001807.
18. Ordoñez CA, Rodríguez F, Orlas CP, Parra MW, Caicedo Y, Guzmán M, et al. The critical threshold value of systolic blood pressure for aortic occlusion in trauma patients in profound hemorrhagic shock. *J Trauma Acute Care Surg* 2020;89:1107-13. Doi: 10.1097/TA.0000000000002935.
19. Melendez JJ, Caicedo Y, Guzman M, Serna JJ, Ordoñez J, Angamarca E, et al. Prehospital Damage Control: The Management of Volume, Temperature...and Bleeding! *Colomb Med (Cali).* 2020; 51(4): e4024486. Doi: 10.25100/cm.v51i4.4486.
20. Mejia DA, Parra M, Ordoñez CA, Padilla N, Caicedo Y, Pereira-Warr S, et al. Hemodynamically Unstable Pelvic Fracture: A Damage Control Surgical Algorithm that Fits your Reality. *Colomb Med (Cali).* 2020; 51(4): e4214510. Doi: 10.25100/cm.v51i4.4510.
21. Ordoñez CA, Rodríguez F, Parra M, Herrera JP, Guzmán-Rodríguez M, Orlas C, et al. Resuscitative endovascular balloon of the aorta is feasible in penetrating chest trauma with major hemorrhage: Proposal of a new institutional deployment algorithm. *J Trauma Acute Care Surg* 2020;89:311-9. Doi: 10.1097/ta.0000000000002773.
22. Ordoñez CA, Parra M, Caicedo Y, Padilla N, Rodríguez F, Serna JJ, et al. REBOA as a new damage control component in hemodynamically unstable noncompressible torso hemorrhage patients. *Colomb Med (Cali).* 2020; 51(4): e4064506. Doi: 10.25100/cm.v51i4.4506
23. Salamea JC, Himmler A, Valencia-Angel LI, Ordoñez CA, Parra M, Caicedo Y, et al. Whole Blood for Blood Loss: Hemostatic Resuscitation in Damage Control. *Colomb Med (Cali).* 2020; 51(4): e4044511. Doi: 10.25100/cm.v51i4.4511.