




English Version



Versión Español



Crossmark



OPEN ACCESS

Citation: Molano PE, Duque JS, Urbano GDM **Simultaneous periodontal and endodontic surgery: report of four clinical cases.** Colomb Méd (Cali),2024; 55(2):e5006363. <http://doi.org/10.25100/cm.v55i2.6363>

Received: 19 Feb 2024

Revised: 26 May 2024

Accepted : 29 Jun 2024

Published: 30 Jun 2024

Keywords:

Endodontic surgery, periodontal disease, periapical, periodontitis, case report.

Palabras clave:

Cirugía endodóntica, cirugía periodontal, enfermedad periodontal, periápice, periodontitis, reporte de caso.

Simultaneous periodontal and endodontic surgery: report of four clinical cases.

Cirugía simultánea periodontal y endodóntica: reporte de cuatro casos clínicos.

Pablo Emilio Molano,¹  Juan Sebastián Duque F,¹  Deisy Milena Urbano Gómez^{1,2} 

1 Escuela de Odontología, Universidad del Valle, Cali, Colombia, Universidad del Valle. 2 Colegio Odontológico Colombiano, Cali, Colombia

Abstract

Case Description:

Four cases of patients aged 41, 33, 43 and 68 years who presented periapical lesions and needed periodontal surgery for pre-prosthetic purposes.

Clinical Findings:

The first case presented an intra-radicular retainer that was difficult to remove and likely to generate a root fracture. In addition, asymmetry of the gingival zenith was observed. The second case presented a complete crown at 16 with mesial marginal mismatch and subgingival margins distally. The third case presented a vestibular fistula with inflammation at the cervical level. The fourth case presented a vestibular fistula in the upper right lateral incisor. All patients showed apical lesions.

Treatment and Outcome:

The first three cases received coronal lengthening and apical surgery in the same surgical procedure. In the fourth case, apical surgery was performed, and placement of implants 13 and 15 with a pontic of 14. During the clinical control and radiographs performed after the surgical procedures, bone filling of the lesion was found.

Clinical Relevance:

Considering the results obtained, performing the periodontal and endodontic surgery procedures in a single surgical act is suggested. This reduces costs, travel, number of appointments, medication intake and post-surgical complications.

Copyright: © 2024 Universidad del Valle



Conflict of interest:

Ninguno.

Corresponding author:

Pablo Emilio Molano.

Escuela de Odontología,
Universidad del Valle, Cali,
Colombia. Email: [pablo.e.molano@
correounivalle.edu.co](mailto:pablo.e.molano@correounivalle.edu.co)

Resumen

Descripción del caso:

Cuatro casos de pacientes (41 a 68 años) que presentaron lesiones periapicales y necesidad de cirugía periodontal con fines preprotésico.

Hallazgos clínicos:

El primer caso presentó un retenedor intrarradicular difícil de retirar y con posibilidades de generar una fractura radicular; además, se observó asimetría del cenit gingival. El segundo caso presentó una corona completa en el 16 con desadaptación marginal mesial y márgenes subgingivales en distal. El tercer caso presentó una fístula vestibular con inflamación a nivel cervical. El cuarto caso presentó una fístula vestibular en el incisivo lateral superior derecho. Todos los pacientes tenían lesiones apicales.

Tratamiento y resultados:

Los tres primeros casos recibieron cirugía de alargamiento coronal y en el mismo acto quirúrgico una cirugía apical. En el cuarto caso se realizó cirugía apical y colocación de los implantes del 13 y 15 con pónico del 14. Durante el control clínico y radiografías realizadas posterior a los procedimientos quirúrgicos se recuperó el tejido óseo alrededor de la lesión.

Relevancia clínica:

Considerando los resultados obtenidos, se propone realizar en un solo acto quirúrgico los procedimientos de cirugía periodontal y endodóntica. Así, se disminuyen costos, desplazamiento, número de citas, toma de medicamentos y complicaciones posquirúrgicas.

Introduction

Dental destruction caused by caries or traumatic injuries accompanied by pulp involvement leads to the need for root canal treatments prior to oral rehabilitation, and in some cases, periodontal surgery is required for clinical crown lengthening or treatment of periodontal disease^{1,2}. Indications for endodontic surgery include failure of conventional root canal therapy, limited feasibility of retreatment, and enlargement of an apical lesion. Endodontic surgery can be categorized into apical and periradicular procedures³. In certain cases, both apical surgery and periodontal surgery are required at the same site. The aim of this case series is to establish the indications, contraindications, and surgical techniques for cases where both procedures are needed, thus avoiding multiple surgical sessions, reducing costs, and minimizing potential postoperative complications.

Case report

Case # 1

A 41-year-old male patient with no systemic history presented with a 6 mm diameter apical radiolucent area on the upper right central incisor (tooth 11) that did not improve with conventional endodontic treatment. The diagnosis was previously treated tooth with chronic apical periodontitis. The crown had a core build-up with an intraradicular post of good length that was difficult to remove and posed a risk of root fracture upon removal, leading to the decision to proceed with apical surgery. Mobility was assessed during the initial examination and re-evaluation. Periodontally, there was an asymmetry in the gingival zenith of tooth 11 compared to teeth 12 and 21; tooth 11 had a width of 10 mm, a length of 7 mm, a diastema of 2 mm, and a groove depth of 5 mm. Based on these findings, a crown lengthening surgery was proposed to the patient using an internal bevel gingivectomy with a 2 mm osteotomy. In the same surgical session, apical surgery would be performed in collaboration with the endodontist (Figure 1 A-B).

Treatment

The surgical procedure began with infiltrative anesthesia on the buccal and palatal sides. The zenith point of the adjacent tooth (tooth 21 as a reference) was measured, a bleeding point was marked apically, followed by an internal bevel incision, an intracrevicular incision, and removal of the gingival collar.

The intracrevicular incisions were extended from tooth 13 to tooth 21, with relaxing incisions made at the mesial of tooth 13 and distal of tooth 21. A mucoperiosteal flap was elevated, revealing loss of the buccal cortical plate at the apical level. Using a Lucas curette, all granulation tissue was removed, followed by a 3 mm apicoectomy with a Zecrya bur, retropreparation with NSK® ultrasonic tips for apical surgery, and retrofilling with Mineral Trioxide Aggregate (MTA) cement. Crown lengthening was then performed to align the alveolar bone height with that of tooth 21. Root planing and scaling were done, the flap was sutured in an apical position, and the patient was prescribed antibiotics with 500 mg of azithromycin once daily for 3 days and 100 mg of nimesulide every 12 hours for 3 days as an analgesic (Figure 2A).

Results and follow-up

A clinical check-up was performed and the stitches were removed one week after the procedures. Normal healing tissue was observed. The temporary tooth was relined after two weeks and an X-ray was taken after 3 months, which showed optimal healing conditions.

After this, the rehabilitation phase continued, where the final impression was taken, the study models were mounted and sent to the laboratory for the fabrication of the metal cap, which was tested, the color was determined and the complete crown was cemented in a definitive manner. Clinically, no changes in tooth mobility were found at the end of the treatment (Figure 2B).

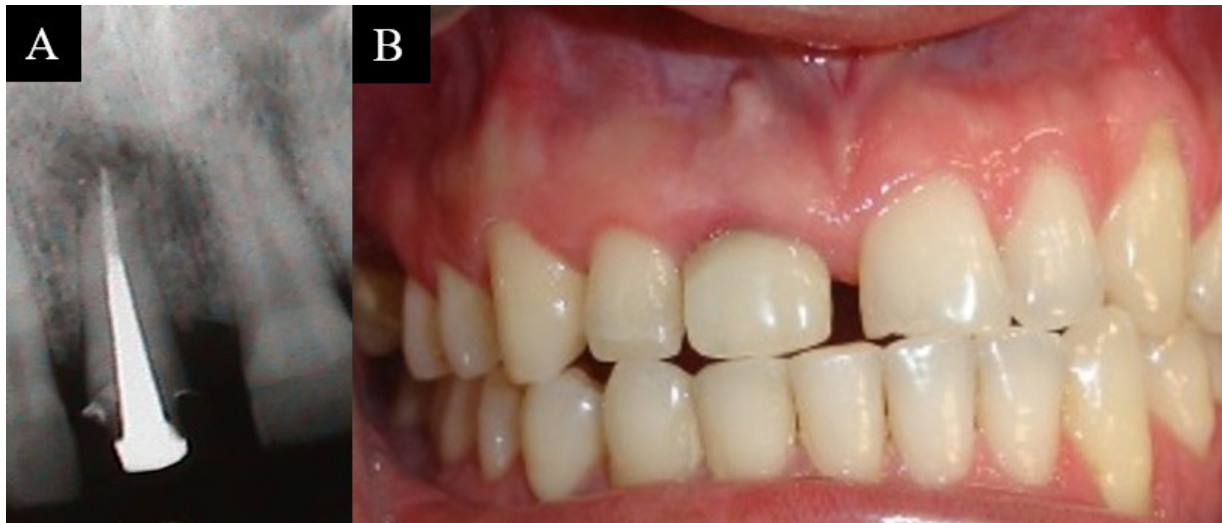

Figure 1. A. Intraradicular post and apical lesion. B. Asymmetry of the gingival zenith on tooth 11.

Case # 2

A 33-year-old patient presented a complete crown on tooth 16 and periodontally, grooves with an average of 3 mm were found, with no tooth mobility, no loss of attachment and mild inflammation. Gingivitis was diagnosed associated with mesial marginal mismatch and subgingival margins in the distal crown of tooth 16 that required crown lengthening surgery.

Radiographic evaluation revealed an extensive apical lesion in the mesial root, leading to a diagnosis of a previously treated tooth and asymptomatic apical periodontitis, with a direct intraradicular retainer of adequate adaptation and length, which is why it was decided to perform periodontal and endodontic surgery in the same procedure (Figure 3A).

Treatment

An intracrevicular incision was made on the vestibular side and an internal bevel and intracrevicular incision on the palatal side, and the gingival collar was removed. A mucoperiosteal flap was elevated and crown lengthening surgery was performed, after which the endodontist continued with the apical surgery. This started with the removal of granulation tissue with a spoon, an apicoectomy of the 3 mm of the mesobuccal root apex was performed with a Zecrya bur, then retro-preparation with ultrasound for NSK® apical surgery, and retro-filling with MTA aggregate cement.

Results and follow-up

The sutures were removed 8 days later, observing normal healing of tissues, and 12 months after the surgical procedures, follow-up by X-ray showed complete bone filling of the apical lesion, indicating good healing. At that time, the patient decided to perform the definitive rehabilitation of tooth 16 (Figure 3B-D).

Case # 3

43-year-old patient presented a vestibular fistula apical to tooth 25. The crowns of teeth 24 and 25 presented 3 mm grooves, inflammation and bleeding on probing, diagnosing gingivitis. In addition, the crowns were small and the subgingival margins invaded the biological

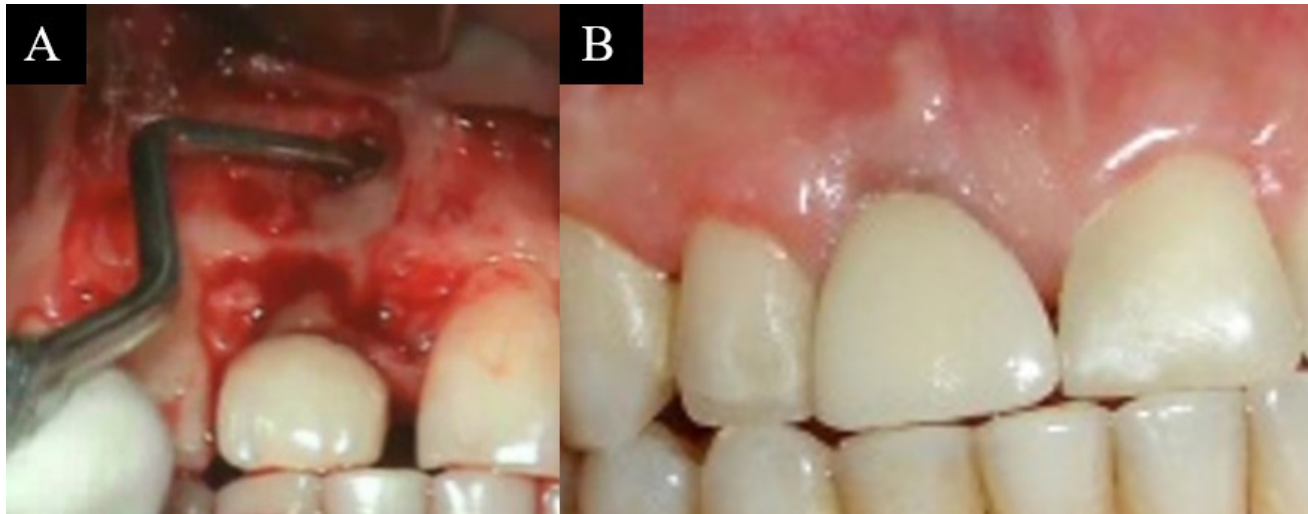


Figure 2. A. Degranulation of the apical lesion and coronal lengthening. B. Final cementation of metal-porcelain crown.

space, which generated inflammation at the cervical level and indicated the need to perform crown lengthening surgery. Radiographically, a coronal and intraradicular radiopaque area compatible with a crown and wide intraradicular retainer was evident in tooth 24, followed by a radiopaque area in the apical third compatible with endodontic filling material, an apical radiolucent area compatible with a periapical lesion, and a diagnosis was made as a previously treated tooth and chronic apical abscess.

Treatment

Coronal lengthening was performed by means of an intracrevicular incision, a mucoperiosteal flap and osteotomy to remove all granulation tissue with a Lucas curette. Subsequently, an apicoectomy was performed with a Zecrya bur, retropreparation with NSK® ultrasound tips, and retrofilling with reinforced glass ionomer (IRM) cement.

Results and follow-up

After one year of surgery, the radiographic image showed complete bone filling of the apical lesion and definitive rehabilitation in optimal conditions (Figure 4 A-C).

Case #4

A 68-year-old patient presented a vestibular fistula in the upper right lateral incisor tooth 12. Periodontally, the patient presented gingivitis, bleeding on probing, and grade 1 mobility. No pockets or active periodontitis were found.

Radiographically, a widening of the periodontal ligament space and an apical radiolucent area were observed in teeth 12 and 16. The diagnosis was pulp necrosis and chronic apical abscess. Conventional endodontics was performed on teeth 12 and 16; however, at a 6-month check-up, it was observed that the diameter of the lesion on tooth 12 had not decreased. Considering these findings, it was decided to perform apical surgery and, in the same surgical procedure, place the implants on teeth 13 and 15 with a pontic on tooth 14.

Treatment

A crestal incision was made from teeth 15 to 13, a buccal and palatal intracrevicular incision from tooth 12 with a relaxing incision mesial to tooth 11. A mucoperiosteal flap was elevated.

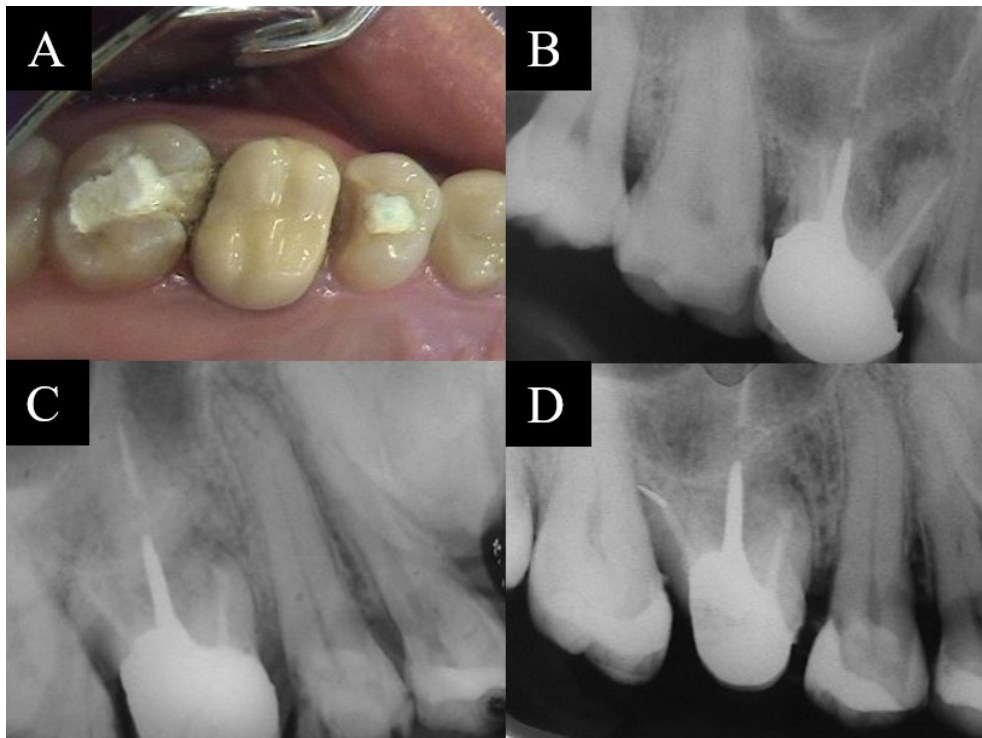


Figure 3. A. Occlusal view of the 16th. B. Radiograph May 2004. C. Radiograph December 2004. D. Radiograph May 2005.

Apical granulation tissue was removed from tooth 12 and apical surgery was performed by removing 3 mm of the apex of tooth 12 with a Zecrya bur, retropreparation with ultrasound tips, and retrofilling with MTA cement.

Subsequently, the implants were placed based on the previously prepared surgical guide. The preparation of the implant bed (Zimmer) was performed to be able to place a 4.1 x 10 mm implant at 15 and a 3.7 x 13 mm implant at 13. Finally, sutures were taken.

Results and follow-up

A clinical and radiographic evaluation was performed after 6 months, which showed complete resolution of the lesion and optimal condition of the implants. The second surgical phase of implants 15 and 13 was performed, as well as definitive rehabilitation.

Consent

Written informed consent was obtained from the patients for publication of this case report and the accompanying images.

Discussion

This report presents four cases with periapical lesions in the upper jaw and the need for periodontal surgery for preprosthetic purposes, for whom a single surgical procedure was used to solve both problems. In this way, the aim was to reduce the number of appointments, treatment costs and possible complications when performing two separate surgical procedures.

Various clinical situations require multidisciplinary management to improve function, well-being and aesthetics¹. Although technological advances in conventional endodontic treatment have reduced the number of cases requiring apical surgery, in some cases it is necessary to perform surgical methods where an orthograde endodontic treatment does not represent the best alternative

or is not possible to perform^{4,5}. Periodontal surgery is performed for the treatment of periodontal disease using conservative or resective techniques, in preprosthetic surgery for lengthening clinical crowns, to cover retractions, and to increase atrophied ridges, among others¹.

The most common procedure, which was used in three of the cases presented here, was crown lengthening surgery, where gum and bone were removed, creating a longer crown that would allow for the retention of a crown and thus avoid invasion of the biological space⁶⁻¹⁴.

Among the most common periodontal problems are gingival hypertrophy, restorative problems such as short clinical crowns, caries, gummy smile, gingival asymmetry¹⁵⁻¹⁹, and altered passive eruption, the latter being the most common pathology^{7,20}. In the reported cases, bleeding was found on probing, which is a clinical sign of inflammatory lesion and is used as an indicator of periodontal status and progression of gingivitis. The surgical techniques used in these cases were mucoperiosteal flap elevation in combination with granulation tissue removal and apicoectomy, which have been documented in previous reports²¹⁻²⁴.

Possible contraindications to performing surgeries simultaneously may occur when the post-surgical remaining root length of the tooth to be treated is unfavorable, or in teeth that are pillars for fixed or removable prostheses where said procedure may affect their prognosis. Likewise, in cases where there are vertical fractures or root bursts, or when the crown-root proportion is greatly altered.

As mentioned above, simultaneous surgeries performed on the patients presented represent a reduction in surgical times, since when they are performed separately, it is necessary to wait 2 to 3 months for the second procedure. Likewise, morbidity and the risk of adverse events are reduced in patients who require the suspension of specific medications for the performance of the surgeries (e.g. anticoagulants). For patients, it also represents a benefit in terms of costs.

A possible complication of performing both surgeries simultaneously may be the risk of increased tooth mobility due to the proximity of the new bone crest to the beginning of the apical lesion in the healing process. In addition, negative alterations in terms of crown-root proportion may occur. However, in the cases presented we had no complications.

It is recommended to have optimal root length and radiographic follow-up before performing definitive rehabilitation.

References

1. Matos CR, Bascones-Martínez A. Tratamiento periodontal quirúrgico: revisión. conceptos. consideraciones. Procedimientos. Técnicas. Av Periodon Implantol. 2011; 23(3): 155-70.
2. Lindhe J, Westfelt E, Nyman S, Socransky SS, Heijl L, Bratthall G. Healing following surgical/non-surgical treatment of periodontal disease A clinical study. J Clin Periodontol. 1982; 9(2): 115-28. doi: 10.1111/j.1600-051x.1982.tb01227.x.
3. Kim S, Kratchman S. Modern endodontic surgery concepts and practice: a review. J Endod. 2006; 32(7): 601-23. doi: 10.1016/j.joen.2005.12.010.
4. Baruwa AO, Martins JNR, Pires MD, Pereira B, Cruz PM, Ginjeira A. Management of apico-marginal defects with endodontic microsurgery and guided tissue regeneration: a report of thirteen cases. J Endod. 2023; 49(9): 1207-15. doi: 10.1016/j.joen.2023.07.009.
5. Setzer FC, Kratchman SI. Present status and future directions: Surgical endodontics. Int Endod J. 2022; 55(Suppl 4): 1020-58. doi: 10.1111/iej.13783.

6. Villaerde G, Carrion B, Barbosa R, Bascones I, Bascones A. Tratamiento quirúrgico de las coronas clínicas cortas: técnica de alargamiento coronario. *Av Periodon Implantol.* 2000; 12: 117-26.
7. Hempton T, Esrason F. Crown lengthening to facilitate restorative treatment in the presence of incomplete passive eruption. *J Can Dent Assoc.* 2000; 28: 290-1.
8. Lai JY, Silvestri L, Girard B. Anterior esthetic crown - lengthening surgery: a case report. *J can dent Assoc.* 2001; 67: 600-3.
9. Mohan S, Lavu V. Gingival Zenith Correction by Laser Gingivectomy. *Cureus.* 2024; 16(1): e51495.
10. Cabrera I, Guerrero F, Peyrallo F. Alargamiento quirúrgico coronario. *Quintessence.* 1997; 10: 442-5.
11. Weinberg MA, Fernandez AR, Scherer W. Delayed passive eruption: an old concept with a distinct guise. *Gen Dent.* 1996; 44(4): 352-5.
12. Bensimon GD. Procedimiento de alargamiento quirúrgico de la corona para mejorar el aspecto estético. *Int J Per Rest Dent* 1999; 19: 333-41.
13. Bruhnke M, Krastl G, Neumeyer S, Beuer F, Herklotz I, Naumann M. Forced orthodontic extrusion to restore the unrestorable: a proof of concept. *Int J Periodontics Restorative Dent.* 2023; 43(5): 560-9.
14. Jorgensen MG, Nowzari H. Aesthetic crown lengthening. *Periodontol.* 2000. 2001; 27: 45-58. doi: 10.1034/j.1600-0757.2001.027001045.x.
15. Dello RNM. Placement of crown margins in patients with altered passive eruption. *Int J Periodontics Restorative Dent.* 1984; 4(1): 58-65.
16. Lai JY, Silvestri L, Girard B. Anterior esthetic crown-lengthening surgery: a case report. *J Can Dent Assoc.* 2001; 67(10): 600-3.
17. Davarpanah M, Jansen CE, Vidjak FMA, Étienne D, Kebir M, Martinez H. Consideraciones restauradoras y periodontales de coronas clínicas cortas. *Rev Int Odont Rest Per.* 1998; 2(5): 401-7.
18. Palomo F, Kopczyk RA. Rationale and methods for crown lengthening. *J Am Dent Assoc.* 1978; 96(2): 257-60. doi: 10.14219/jada.archive.1978.0066.
19. Dolt AH 3rd, Robbins JW. Altered passive eruption: an etiology of short clinical crowns. *Quintessence Int.* 1997; 28(6): 363-72.
20. Coslet JG, Vandarsall RL, Weigold A. Diagnosis and classification of delayed passive eruption of the dentogingival junction in the adult. *Alpha Omegan.* 1977; 70: 24-8.
21. Moreno RJA, Ortiz RAJ. Periodontal granulation tissue preservation in surgical periodontal disease treatment: a pilot prospective cohort study. *J Periodontal Implant Sci.* 2022; 52(4): 298-311. doi:10.5051/jpis.2105780289
22. Correa AJ, Alister JP, Manterola C. Uso de la fibrina rica en plaquetas inyectable (i-prf) en defectos infra óseos en terapia periodontal no quirúrgica. reporte de dos casos. *Int J Odontostomat.* 2019; 13(3): 271-4.
23. Ibrahim AA, Tawfik OK, EINahass H. Partial (incomplete) removal of granulation tissue using modified minimally invasive surgical technique in treatment of infrabony defects (randomized control clinical trial). *BMC Surg.* 2024; 24(1): 230. doi:10.1186/s12893-024-02509-
24. Bahar SÇ, Karakan NC, Vurmaz A. The effects of injectable platelet-rich fibrin application on wound healing following gingivectomy and gingivoplasty operations: single-blind, randomized controlled, prospective clinical study. *Clin Oral Investig.* 2024; 28(1): 85.