Colombia Médica

English version

English version

Check for updates

CrossMark

CASE REPORT

Coexistence of cystic fibrosis and congenital factor XI deficiency in a pediatric patient: a case report

Coexistencia de fibrosis quística y deficiencia congénita de factor XI en una paciente pediátrica: reporte de caso

Michelle Higuera-Carrillo[1,2,3] **Sara Vallejo-Tamayo**[4,5] **Catalina Vasquez-Sagra**[2,3] **Jorge Mario Rueda Rincón**[6,7]

1 Universidad Nacional de Colombia, Faculty of Medicine, Department of Pediatrics, Bogotá, Colombia. **2** Hospital Infantil Universitario de San José, Bogotá, Colombia. **3** Fundación Universitaria de Ciencias de la Salud (FUCS), Bogotá, Colombia. **4** CES University, Faculty of Medicine, Department of Pediatrics, Medellín, Colombia. **5** Pablo Tobón Uribe Hospital, Medellín, Colombia. **6** Surcolombiana University, Neiva, Colombia. **7** Hospital Universitario Hernando Moncaleano Perdomo, Neiva, Colombia.

OPEN ACCESS

Citation: Higuera-Carrillo M, Vallejo-Tamayo S, Vasquez-Sagra C, Rueda Rincón JM. **Coexistence of cystic fibrosis and congenital factor XI deficiency in a pediatric patient: a case report**. Colomb Med (Cali). 2026; 57(2):e5007143. https://doi.org/10.25100/cm.v57i2.7143

Received: 12 Jan 2026
Revised: 07 Jun 2026
Accepted: 30 Jun 2026
Published: 30 Jun 2026

Keywords

Cystic Fibrosis; Factor XI Deficiency; Blood Coagulation Disorders; Exocrine Pancreatic Insufficiency.

Palabras clave

Fibrosis Quística; Deficiencia del Factor XI; Trastornos de la Coagulación Sanguínea; Insuficiencia Pancreática Exocrina.

Abstract

Introduction

Cystic fibrosis may be associated with coagulation abnormalities secondary to vitamin K malabsorption or hepatobiliary dysfunction. However, isolated prolongation of the activated partial thromboplastin time (aPTT) warrants investigation of alternative causes, including inherited coagulation factor deficiencies.

Case presentation

An 11-year-old girl with cystic fibrosis confirmed by sweat chloride testing and molecular analysis, carrying the *CFTR* c.3846G>A variant, presented with severe exocrine pancreatic insufficiency and predominantly gastrointestinal manifestations. During hospitalization, she exhibited persistently prolonged aPTT with a normal international normalized ratio (INR). Hematological evaluation revealed reduced factor XI activity (33 IU/dL), with normal levels of factors VIII, IX, XIII, and von Willebrand factor, consistent with factor XI deficiency.

Discussion

Although coagulation abnormalities in cystic fibrosis are commonly associated with vitamin K deficiency or hepatobiliary involvement, the identification of factor XI deficiency suggests an unusual concomitant diagnosis. This finding highlights the importance of interpreting coagulation tests according to their specific pattern of abnormalities and considering conditions independent of the underlying disease, particularly given their implications for bleeding risk.

Conclusion

Persistent isolated aPTT prolongation in patients with cystic fibrosis should not automatically be attributed to nutritional or hepatobiliary complications. Targeted hematological evaluation may identify concomitant coagulation disorders and guide clinical management.

Copyright © 2026 Universidad del Valle

Conflict of interest

The authors declare no conflicts of interest related to the preparation, content, or publication of this manuscript.

Funding

This work received no specific funding from any public, commercial, or not-for-profit funding agency.

CRediT authorship contribution statement

M.H-C: Conceptualization, Methodology, Investigation, Data curation, Writing - original draft, Writing - review & editing. **S.V-T:** Conceptualization, Methodology, Investigation, Formal analysis, Writing - original draft, Writing - review & editing. **C.V-S:** Investigation, Data curation, Validation, Writing - review & editing. **J.M.R.R:** Investigation, Validation, Supervision, Writing - review & editing.

Corresponding author

Michelle Higuera-Carrillo, email: michellehiguera@yahoo.com.

Resumen

Introducción

La fibrosis quística puede asociarse con alteraciones de la coagulación secundarias a malabsorción de vitamina K o disfunción hepatobiliar. Sin embargo, la prolongación aislada del tiempo de tromboplastina parcial activada (TTPa) requiere investigar otras causas, incluidas las deficiencias hereditarias de factores de coagulación.

Presentación del caso

Paciente femenina de 11 años con fibrosis quística confirmada mediante pruebas de sudor y estudio molecular, portadora de la variante *CFTR* c.3846G>A, con insuficiencia pancreática exocrina grave y predominio de manifestaciones gastrointestinales. Durante una hospitalización presentó prolongación persistente del TTPa con índice internacional normalizado (INR) normal. El estudio hematológico evidenció actividad reducida del factor XI (33 UI/dL), con niveles normales de los factores VIII, IX, XIII y del factor de von Willebrand, hallazgos compatibles con deficiencia de factor XI.

Discusión

Aunque las alteraciones de la coagulación en la fibrosis quística suelen relacionarse con deficiencia de vitamina K o compromiso hepatobiliar, la identificación de una deficiencia de factor XI plantea un diagnóstico concomitante poco habitual. Este hallazgo destaca la importancia de interpretar las pruebas de coagulación según su patrón de alteración y de considerar causas independientes de la enfermedad de base, especialmente por sus implicaciones en el riesgo hemorrágico.

Conclusión

En pacientes con fibrosis quística, la prolongación persistente y aislada del TTPa no debe atribuirse automáticamente a complicaciones nutricionales o hepatobiliares. Una evaluación hematológica dirigida permite identificar trastornos concomitantes de la coagulación y orientar el manejo clínico.

Introduction

Cystic fibrosis (CF) is a multisystem autosomal recessive disorder caused by pathogenic variants in the *CFTR* gene, with highly heterogeneous clinical manifestations [1,2]. Although respiratory involvement is a hallmark of the disease, gastrointestinal and hepatobiliary complications, particularly exocrine pancreatic insufficiency, fat-soluble vitamin malabsorption, and cystic fibrosis-related liver disease, remain important determinants of prognosis and quality of life in pediatric patients [3,4].

Cystic fibrosis is a multisystem disorder in which coagulation abnormalities are relatively common but are typically secondary to well-established mechanisms, including vitamin K deficiency resulting from fat malabsorption, subclinical cholestasis, or hepatic dysfunction. These abnormalities usually manifest as prolongation of prothrombin time (PT) or an elevated international normalized ratio (INR), which often normalize following vitamin supplementation and optimization of nutritional support. However, persistent prolongation of activated partial thromboplastin time (aPTT) with a normal INR represents an atypical and clinically challenging pattern. This discrepancy suggests a primary defect in the intrinsic coagulation pathway, as observed in inherited deficiencies of factors XI, IX, or XII, or in the presence of circulating coagulation inhibitors. The coexistence of cystic fibrosis and a congenital intrinsic pathway coagulopathy is exceptionally rare and has been scarcely described in the pediatric literature.

We present the case of a girl with molecularly confirmed cystic fibrosis carrying the pathogenic *CFTR* c.3846G>A variant and exhibiting a predominantly gastrointestinal phenotype, who was found to have persistently prolonged aPTT, a normal INR, reduced factor XI activity, and no evidence of advanced liver disease. This unusual clinical presentation suggested a concomitant

primary coagulation disorder. This case highlights the importance of expanding the diagnostic evaluation when the pattern of coagulation abnormalities is inconsistent with the complications typically associated with cystic fibrosis. Such an approach enables clinicians to distinguish hemostatic abnormalities secondary to the underlying disease from those due to a coexisting congenital coagulopathy, with important implications for bleeding risk assessment and the planning of invasive procedures.

Case report

We report the case of an 11-year-old girl with no relevant perinatal or family history and an International Society on Thrombosis and Haemostasis Scientific and Standardization Committee (ISTH-SSC) Bleeding Assessment Tool (BAT) score of 2. Biochemical evidence consistent with CF was identified in early childhood: a sweat chloride test performed at 2 years of age was positive (93 mmol/L), and a second test at 4 years of age was also positive (90 mmol/L). At 9 years of age, she began follow-up in a specialized multidisciplinary care program after a clinical course predominantly characterized by persistent gastrointestinal symptoms, including intermittent abdominal pain, abdominal distension, and chronic constipation, accompanied by mild but persistently elevated aminotransferase levels. Genetic testing identified the pathogenic *CFTR* variant c.3846G>A, supporting the diagnosis of cystic fibrosis with a predominantly gastrointestinal phenotype. The patient had severe exocrine pancreatic insufficiency (fecal elastase, 1.7 µg/g), requiring continuous pancreatic enzyme replacement therapy, fat-soluble vitamin supplementation, and regular treatment with osmotic laxatives for intestinal dysmotility. In contrast, pulmonary involvement was minimal, with preserved lung function (forced expiratory volume in one second [FEV1], 100-114% of predicted), no significant pulmonary exacerbations, and no chronic colonization with *Pseudomonas aeruginosa*.

During hospitalization, the patient had a persistently prolonged aPTT with a normal INR. This pattern was unlikely to be explained by vitamin K deficiency or cystic fibrosis-related liver disease, raising suspicion for a primary disorder of the intrinsic coagulation pathway. Consequently, an expanded hematologic evaluation was performed, revealing reduced factor XI activity (33 IU/dL), while factor VIII, IX, XIII, and von Willebrand factor levels remained within normal ranges. These findings were consistent with congenital factor XI deficiency, also known as hemophilia C, a rare inherited bleeding disorder whose coexistence with cystic fibrosis is exceptionally uncommon (Figure 1). The identification of these findings supported the coexistence of cystic fibrosis and a congenital coagulopathy, with important implications for bleeding risk assessment and the planning of invasive procedures.

Discussion

Cystic fibrosis is a multisystem disease in which gastrointestinal and hepatobiliary involvement represents a major contributor to morbidity. Exocrine pancreatic insufficiency, which is highly prevalent among these patients, leads to chronic malabsorption of fats and fat-soluble vitamins, including vitamin K. At the same time, cholestasis and cystic fibrosis-related liver disease increase the risk of progressive impairment of hepatic synthetic function [5]. Consequently, hemostatic abnormalities observed in patients with CF are generally secondary to these mechanisms and predominantly affect the extrinsic coagulation pathway, typically manifesting as prolonged PT or an elevated INR [4].

When coagulation abnormalities are identified in patients with cystic fibrosis, it is essential to distinguish disorders that predominantly affect the extrinsic coagulation pathway (manifested by prolonged PT or elevated INR) from those that involve the intrinsic pathway (manifested by prolonged aPTT), as illustrated in Figure 2. In patients with CF, coagulation abnormalities are commonly attributable to the mechanisms described above. However, in our patient, the absence of biochemical or elastographic findings suggestive of advanced liver disease, together with a persistently normal INR, made it unlikely that the isolated prolongation of aPTT was secondary to cystic fibrosis.

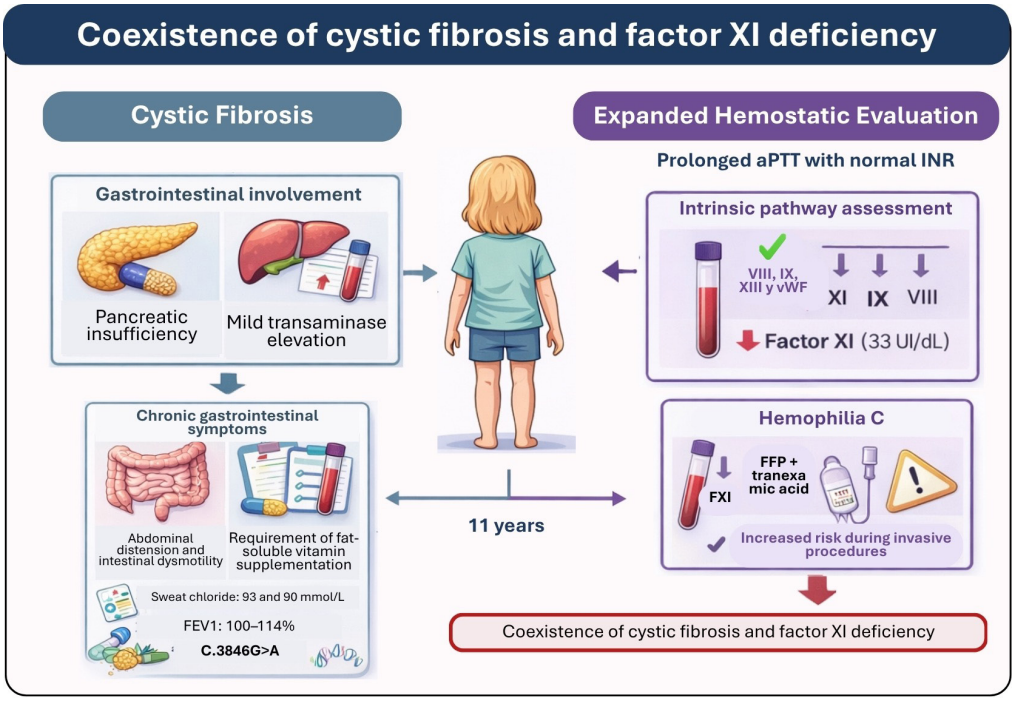

Figure 1. Schematic representation of the coexistence of cystic fibrosis and factor XI deficiency in a pediatric patient. The predominantly gastrointestinal phenotype and coagulation abnormalities are highlighted, characterized by isolated prolongation of activated partial thromboplastin time (aPTT), a normal international normalized ratio (INR), and reduced factor XI activity. Created by the authors.

In our patient, persistent isolated prolongation of aPTT, with a consistently normal INR, was a key finding that prompted a broader differential diagnostic evaluation beyond the hemostatic abnormalities traditionally associated with cystic fibrosis. The differential diagnosis included inherited deficiencies of intrinsic coagulation pathway factors (VIII, IX, XI, or XII), specific coagulation inhibitors, lupus anticoagulant, and, although less common in pediatric patients, unrecognized medication exposure [6,7]. An expanded hematologic evaluation revealed normal levels of factors VIII, IX, and XIII, as well as von Willebrand factor, whereas factor XI activity was reduced (33 IU/dL). These findings identified a specific coagulation abnormality consistent with factor XI deficiency.

In this context, confirmation of reduced factor XI activity was the key finding, providing a coherent explanation for the observed hemostatic profile. Factor XI deficiency, also known as hemophilia C, is a rare inherited bleeding disorder with an estimated prevalence of approximately 1 in 1,000,000 individuals in the general population. Its prevalence is higher in certain founder populations, particularly Ashkenazi Jews, among whom the frequency of heterozygous carriers may reach 8% [8,9]. The disorder is characterized by a highly variable bleeding phenotype, ranging from minimal bleeding manifestations to disproportionate hemorrhage following surgical procedures or trauma [10]. Identifying factor XI deficiency in a patient with cystic fibrosis is clinically relevant because it has important implications for bleeding risk assessment, the planning of invasive procedures, and therapeutic decision-making.

Unlike hemophilia A or B, hemophilia C generally does not require routine prophylactic treatment in the absence of bleeding. Management primarily focuses on preventing hemorrhagic complications associated with invasive procedures, surgery, or trauma. Therapeutic strategies include fresh frozen plasma as a source of factor XI replacement and antifibrinolytic agents, such as tranexamic acid, for selected procedures with a low bleeding risk. In specific clinical circumstances and under hematology supervision, factor XI concentrates may also be considered. However, their availability is limited, and their use may be associated with an increased risk of thrombosis [10,11].

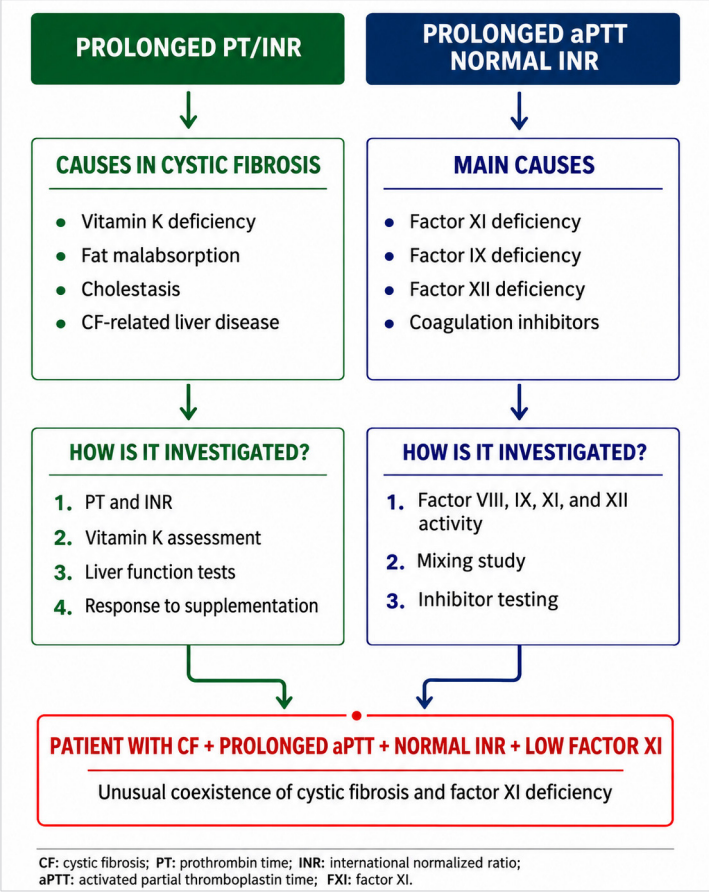

Figure 2. Diagnostic algorithm for coagulation abnormalities in patients with cystic fibrosis. While prolonged PT or an elevated INR is commonly associated with vitamin K malabsorption or cystic fibrosis-related liver disease, persistent isolated prolongation of aPTT with a normal INR should prompt investigation of intrinsic coagulation pathway disorders, including factor XI deficiency. The coexistence of cystic fibrosis and factor XI deficiency represents an unusual clinical finding, with no established evidence of a causal relationship between these conditions. Created by the authors [6,7].

To our knowledge, no pediatric cases describing the coexistence of cystic fibrosis and hemophilia C have been reported in the published literature. Epidemiological studies and comprehensive reviews of factor XI deficiency, including case reports and multicenter series, have not identified cystic fibrosis as an associated comorbidity, and most published cases involve patients without concomitant inherited multisystem disorders [10,12,13]. Nevertheless, the absence of previously reported cases does not constitute evidence of an association between these conditions. Rather, based on the currently available evidence, this case should be interpreted as the coexistence of two rare inherited disorders, with no epidemiological, genetic, or pathophysiological evidence supporting a causal relationship between them.

Conclusion

This case illustrates that persistent prolongation of activated partial thromboplastin time (aPTT) in a pediatric patient with cystic fibrosis should not automatically be attributed to vitamin K malabsorption or disease-related hepatic dysfunction. The finding of prolonged aPTT with a consistently normal international normalized ratio (INR) represents a discordant hemostatic pattern that warrants a broader diagnostic approach to investigate rare primary coagulation disorders.

Identifying factor XI deficiency can guide bleeding risk assessment and the planning of preventive measures for invasive procedures. Recommended preventive measures include preoperative evaluation by pediatric hematology, individualized bleeding risk stratification

based on bleeding history and procedure characteristics, and consideration of antifibrinolytic agents, such as tranexamic acid, for selected interventions. For procedures associated with a high bleeding risk, replacement therapy with fresh frozen plasma may be required, according to hematologic assessment. These recommendations highlight the importance of a multidisciplinary approach to optimizing patient safety in individuals with concomitant coagulation disorders.

This report underscores the value of pathophysiological interpretation of laboratory findings beyond automated algorithms. It highlights the need for a multidisciplinary approach in complex clinical scenarios in which two chronic diseases may coexist and substantially modify the patient's risk profile.

Ethical considerations

Written informed consent for publication of this case report was obtained from the patient's legal representatives.

References

1. Sun BZ, Sawicki GS. Advances in care and outcomes for children with cystic fibrosis. Clin Chest Med. 2024;45(3):625–637. doi: 10.1016/j.ccm.2024.03.006. [CrossRef] [Google Scholar]

2. Azoicai AN, Lupu A, Trandafir LM, Alexoae MM, Alecsa M, Starcea IM, et al. Cystic fibrosis management in pediatric population-from clinical features to personalized therapy. Front Pediatr. 2024;12:1393193. doi: 10.3389/fped.2024.1393193. [CrossRef] [Google Scholar]

3. Dana J, Debray D, Beaufrère A, Hillaire S, Fabre M, Reinhold C, et al. Cystic fibrosis-related liver disease: clinical presentations, diagnostic and monitoring approaches in the era of CFTR modulator therapies. J Hepatol. 2022;76(2):420–434. doi: 10.1016/j.jhep.2021.09.042. [CrossRef] [Google Scholar]

4. Smith K, Black R, Thomas T, Unanyan L, Bass R. Gastrointestinal manifestations in cystic fibrosis. Curr Treat Options Pediatr. 2025;11:31. doi: 10.1007/s40746-025-00351-7. [CrossRef] [Google Scholar]

5. O'Sullivan BP, Freedman SD. Cystic fibrosis. Lancet. 2009;373(9678):1891–1904. doi: 10.1016/S0140-6736(09)60327-5. [CrossRef] [Google Scholar]

6. Chowdary P, Carcao M, Kenet G, Pipe SW. Haemophilia. Lancet. 2025;405(10480):736–750. doi: 10.1016/S0140-6736(24)02139-1. [CrossRef] [Google Scholar]

7. Meral G, Yozgat AK, Çulha V, Güzelküçük Z, Özbek NY, Yaralı HN. The importance of incidentally detected coagulation abnormalities in children. Pediatr Int. 2025;67(1):e70131. doi: 10.1111/ped.70131. [CrossRef] [Google Scholar]

8. Duga S, Salomon O. Congenital factor XI deficiency: an update. Semin Thromb Hemost. 2013;39(6):621–631. doi: 10.1055/s-0033-1353420. [CrossRef] [Google Scholar]

9. Salomon O, Seligsohn U. New observations on factor XI deficiency. Haemophilia. 2004;10(Suppl 4):184–187. doi: 10.1111/j.1365-2516.2004.00992.x. [CrossRef] [Google Scholar]

10. Barg AA, Livnat T, Kenet G. Factor XI deficiency: phenotypic age-related considerations and clinical approach towards bleeding risk assessment. Blood. 2024;143(15):1455–1464. doi: 10.1182/blood.2023020721. [CrossRef] [Google Scholar]

11. Bolton-Maggs PHB. Factor XI deficiency--resolving the enigma? Hematology Am Soc Hematol Educ Program. 2009:97–105. doi: 10.1182/asheducation-2009.1.97. [CrossRef] [Google Scholar]

12. Mandal S, Gami S, Shah S. A case report on an extremely rare disease: factor XI deficiency. Cureus. 2020;12(10):e10746. doi: 10.7759/cureus.10746. [CrossRef] [Google Scholar]

13. Franchini M, Marano G, Pupella S, Vaglio S, Masiello F, Veropalumbo E, et al. Rare congenital bleeding disorders. Ann Transl Med. 2018;6(17):331. doi: 10.21037/atm.2018.08.34. [CrossRef] [Google Scholar]